

Focus on PoCUS or hocus pocus? Integrating point-of-care ultrasound into residency and clinical practice

L. VERNIEUWE (*), P. VAN DE PUTTE (**), J. DEEN (***), S. BOUCHEZ (****)

Abstract : Point-of care ultrasound (PoCUS) is a new clinical diagnostic paradigm that plays an instrumental role in the ongoing anesthesiologist's evolving role towards a perioperative physician. Currently, there are few approved curricula that incorporate a PoCUS program into anesthesia residency. This article examines relevant PoCUS applications for anesthesiologists, presents an overview of existing international guidelines for education and training, and reflects on the need for specialty-wide standards. We present a possible framework, that could offer a first move towards a structured PoCUS pathway for Belgian anesthesia residents and facilitate its incorporation into national anesthesia practice.

Key words : Ultrasound ; point-of-care ; residency ; education ; curriculum ; anesthesia.

WHY THE NEED FOR THIS ARTICLE?

The anesthesiologist's role is evolving worldwide to the role of a "perioperative" physician, providing care for patients before, during and after surgery within perioperative surgical home structures (1). Ultrasonography plays an increasing and instrumental role in that evolution. Historically, the anesthetic community first embraced ultrasound to guide interventions in regional anesthesia and vascular access, where it evolved from the practice of few experts to a "gold standard" used in virtually all anesthesiology practices. This has expanded to an approach where the "whole body" can be examined with ultrasound at the bedside, to answer a well-defined clinical question. This point-of care ultrasound (PoCUS) approach is a new clinical diagnostic paradigm that is considered as the 21st century extension of the physical exam (2).

Emergency and Intensive Care medicine societies were the first to embrace and integrate the use of PoCUS into daily practice and resident training programs by establishing credentialing, training guidelines and proficiency evaluation (3).

Despite the many PoCUS applications, the ample evidence that it improves patient outcomes with high sensitivity and specificity (4), the large interest among junior anesthesiologists and the explosive number of publications and workshops, there are currently few approved didactic requirements or guidelines to incorporate an anesthesia-related PoCUS curriculum. Numerous resident programs include ultrasound-guided locoregional anesthesia and transesophageal echocardiography, but only few rotations offer specific PoCUS training possibilities. This lack of a clear anesthesia-related track and vision leads to disparity in training level among practitioners, makes it difficult to evaluate individual skills, and poses the risk of (trainee) anesthesiologists performing ultrasound exams without having the appropriate know-how to do so, and self-teaching with variable results. PoCUS is an essential skill and each anesthesia practitioner should be able to embrace these new opportunities and achieve competence to provide optimal patient care.

The purpose of this article is to examine relevant PoCUS applications for anesthesiologists, to present an overview of existing international guidelines for education and training, to reflect on the need for specialty-wide standards, and to offer a first move towards a structured PoCUS pathway for Belgian anesthesia residents.

Lynn VERNIEUWE, MD ; Peter VAN DE PUTTE, MD, PhD ; Jasper DEEN, MD ; Stefaan BOUCHEZ, MD.

(*) Department of Anesthesia, University Hospital Antwerpen, Wilrijkstraat 10, 2650 Edegem

(**) Department of Anesthesia, Imeldaziekenhuis, Imeldalaan 9, 2820 Bonheiden, Belgium

(***) Intensive Care Department, ZNA Middelheim, Lindendreef 1, 2020 Antwerpen, Belgium

(****) Department of Anesthesia, Ghent University Hospital, Corneel Heymanslaan 10, 9000 Gent, Belgium

Corresponding author : Peter Van de Putte, MD, Department of Anesthesia, Imeldaziekenhuis, Imeldalaan 9, 2820 Bonheiden, Belgium.

E-mail : doktervdputte@gmail.com

Paper submitted on Dec 31, 2019 and accepted on May 08, 2020

Conflict of interest : None

WORKING DEFINITION OF PoCUS

Certain characteristics are shared by all PoCUS applications (5):

- The examination is done at the bedside within a limited time frame.
- The examination is carried out for a defined condition where ultrasound has been proven to promote care or in which it is the primary diagnostic facility.
- The examination is focused (“goal-oriented” or “limited”) and developed to answer a well-defined clinical diagnostic question that guides care and/or to view real-time physiologic response to specific therapies. This is in contradiction with the radiologist, who performs a more comprehensive assessment.
- The exam answers questions in a binary fashion, being yes/no or present/absent. The objective is not making a final diagnosis, but rather gathering crucial intel to assess the patient, to refine the differential diagnosis, and to elect interventions that change management (6).
- The exam should be defined by easily identifiable findings (“simple questions, straightforward examinations and useful answers”).

- The exam should be easy to learn.

RELEVANT PoCUS APPLICATIONS FOR THE ANESTHESIOLOGIST

We believe the main PoCUS applications taught to residents should include : (1) airway, (2) lung, (3) hemodynamic status, (4) cardiac, (5) vascular access, and (6) abdominal. We have excluded US-guided regional anesthesia, which many users do not see as PoCUS.⁷ We divide these applications into basic and advanced skills and make a distinction between diagnostic and therapeutic applications of PoCUS (Table 1).

Airway ultrasound

Ultrasound can identify upper airway anatomical landmarks such as the thyroid gland, the cricoid and tracheal cartilages, the cricothyroid membrane and the esophagus (8, 9). It has proven to be useful to preoperatively assess the airway and predict difficult intubation (10). Ultrasound can also locate the trachea and the cricothyroid membrane before an anticipated difficult intubation. A pilot study suggested an association between the inability

Table 1
PoCUS applications

	BASIC		ADVANCED	
	Diagnostic	Therapeutic	Diagnostic	Therapeutic
Airway	Correct ETT placement		Vocal cord assessment	Cricothyroidotomy
	Localization thyroid and cricothyroid membrane			Tracheostomy
Breathing	Detection pneumothorax		Differentiation of pleural/pulmonary pathology	Thoracocentesis
	Detection pleural effusion, consolidation, atelectasis		Diaphragm assessment	Chest drain placement
Hemodynamic status	Inferior Vena Cava collapsibility		End Diastolic Left Ventricular volume assessment	
			Left Ventricular Outflow Tract assessment	
Cardiac	Basic TTE (FATE)		Advanced TTE	Pericardiocentesis
	Peri-resuscitation imaging		TEE	
Vascular access		Peripheral venous access		
		Central venous access		
		Arterial access		
Abdominal	FAST			
	Gastric ultrasound (content & volume)		Assessment of aorta dissection and aneurysm	Guidance of paracentesis
	Assessment of fetal heart activity Abdominal aorta assessment			

ETT = endotracheal tube ; TTE = transthoracic echocardiography ; TEE = transesophageal echocardiography ; FATE = Focused Assessed Transthoracic Echo ; FAST = Focused Assessment with Sonography for Trauma.

to visualize the hyoid bone sublingually and difficult direct laryngoscopy (11). The distance between the hyoid bone and the mandibular mentum (hyomental distance ratio) can be a predictor of difficult laryngoscopy in morbidly obese patients (12). In children and young adults, ultrasound is a reliable tool for measuring the diameter of the subglottic airway. The diameter of the left main stem bronchus, and thus the correct size of a left-sided double lumen tube, can be predicted with ultrasound (8). Ultrasound can accurately verify positioning of the endotracheal tube (sensitivity 98.7%, specificity 97.1%) (13). More advanced skills include assessing the mobility of the vocal cords (e.g. after surgery at risk for damaging the recurring laryngeal nerve), and guidance of invasive procedures such as cricothyroidotomy or tracheostomy (9).

Breathing : lung ultrasound

Lichtenstein and Mezière published a paper in 2008 describing the 'Bedside lung ultrasound in emergency' (BLUE) protocol (14). This showed a very good diagnostic accuracy of lung ultrasound for respiratory failure. PoCUS can also be used to detect and to estimate the volume of pleural effusions with high accuracy (93% sensitivity and 96% specificity) (15, 16). Bilateral lung sliding confirms ventilation of both lungs and thus correct position of the endotracheal tube (trachea widening and double bullet sign are additional signs) (17). This can be helpful in case of acute desaturation as lung ultrasound will be able to confirm adequate bilateral ventilation or to confirm correct double lumen tube placement by checking the absence of lung sliding in the non-ventilated lung (8, 19).

Lung ultrasound is more accurate than chest radiography for the detection of a pneumothorax with a higher sensitivity (78.6% vs 39.8%) and similar specificity (98.4% vs 99.3%) (20) and is also superior to chest radiography to detect interstitial syndromes. A recent review showed that B-lines had a sensitivity of 94% and specificity of 92% for acute cardiogenic pulmonary edema (21). Ultrasound also detects early atelectasis and can be used to assess the effectiveness of recruitment maneuvers and to adjust ventilation parameters to prevent atelectasis (22). Lastly, ultrasound is an important tool in improving the safety of thoracentesis, as ultrasound-guided thoracentesis reduces the incidence of pneumothorax or dry tap, compared to clinical guidance (23).

Circulation: Hemodynamic status assessment

Fluid status and responsiveness are frequent concerns in the perioperative setting. Excessive fluid resuscitation increases intensive care unit length of stay, morbidity and mortality (24). Distinguishing responders from non-responders prior to administering large volumes of fluid should be one of the goals of resuscitation. PoCUS can evaluate the hemodynamic status of hypotensive patients and determine the etiology of a shock. A practical echocardiographic view for preload assessment is the transgastric short axis on transesophageal echography (TEE) or parasternal short axis view on transthoracic echocardiography (TTE), which is feasible in most patients under anesthesia (25-27). Ultrasound can evaluate inferior vena cava (IVC) respiratory variations, which can indicate fluid responsiveness, both in mechanically ventilated and in spontaneously breathing patients (24, 27-29). More advanced skills for ultrasound in assessing hemodynamic status include measuring ventricular filling pressures and assessing left ventricular outflow tract.

Circulation : cardiac transthoracic ultrasound

Ultrasound can be used to evaluate ventricular dimensions and systolic function, rule out pericardial effusion and assess gross anatomical abnormalities or signs of chronic heart disease. Many protocols with varying acronyms have been developed (FATE, FoCUS, FEEL), but all are examinations that fulfil the criteria of PoCUS. Kobal et al. found that the accuracy of cardiovascular diagnoses made by medical students using ultrasound was superior to that of cardiologists using standard physical examination techniques (30). More advanced applications of TTE include specific measurements such as cardiac output evaluation, left and right ventricular diastolic assessment, and left ventricular ejection fraction. TEE is considered an advanced application of PoCUS (31).

Guidance of pericardiocentesis is an ultrasound-guided application of PoCUS, and the current technique of choice with the higher success and the lower complication rate compared to blind methods (32).

Vascular access

Ultrasound has long been used to aid central venous access and has evolved into a reliable aid for difficult peripheral venous and arterial catheter

placement. It reduces procedure time, needle insertion attempts, and redirections compared to traditional approaches (33-36). We decided to include US-guided vascular access as a PoCUS skill despite it being omnipresent and therefore excluded by some practitioners from the PoCUS forum (7).

Abdominal ultrasound

The main application of PoCUS in the abdominal region is the FAST (Focused Assessment with Sonography for Trauma) examination that evaluates the presence of intra-peritoneal free fluid. In addition, the subcostal view allows for the rapid detection of a pericardial effusion. PoCUS detects free intra-peritoneal fluid with high accuracy, and it can detect up to 100 mL of free fluid in trained hands (38, 39). The entire scan can be performed in 3-4 minutes. The ability to easily repeat the examination is an extra benefit, especially in cases of high clinical suspicion but with initial negative examinations (38).

Ultrasound can also be used to assess abdominal aorta diameter and to rule out aortic dissection or rupturing aneurysms. A meta-analysis showed a pooled sensitivity of 97.5% and specificity of 98.9% when compared to gold standard testing (39).

Another application of abdominal ultrasound is gastric ultrasound, which can be used to assess aspiration risk. It can determine the nature of the content (empty, clear fluid, thick fluid/solid) and when clear fluid is present, its volume can be estimated. Possible clinical scenarios where gastric ultrasound is useful are urgent or emergency surgery, the presence of severe co-morbidities that may prolong gastric emptying (diabetes, renal or liver dysfunction, or neurological disorders), unreliable or unclear history, and lack of adherence to fasting instructions (40, 41).

Focused obstetrical ultrasound (OBUS) by emergency physicians is highly accurate in confirming intra-uterine pregnancy. A trained provider can perform first trimester ultrasound and use it to assess fetal heart rate as soon as 7-8 weeks of gestation (42).

In addition to the diagnostic applications of abdominal ultrasound, it can also guide paracentesis of intra-abdominal fluid with low risk of complications (43).

WHAT ARE THE EXISTING GUIDELINES FOR PoCUS EDUCATION AND TRAINING?

A PubMed search was performed in May 2019 using the mesh words “point of care ultrasound” and

“curriculum”. Exclusion criteria were languages other than English and articles concerning the pediatric population. The results showed 115 articles, of which 24 were eliminated based on title. Of the 91 articles that remained, 48 were specific for emergency medicine and/or critical care, 30 discussed the implementation of PoCUS education during medical training, 2 provided a radiologist’s point of view, and 3 could not be classified into any of the previous categories. Of the 115 articles, 8 articles were specifically related to anesthesia (28, 44-50). Some articles provided an overview of current curricula and discussed the need for international guidelines, other discussed the best didactic techniques to teach PoCUS to residents.

The only published national ultrasound curriculum is the one of the Royal College of Anaesthetists of Great Britain and Ireland and the Intensive Care Society (51). They propose a curriculum of 12 months’ duration divided into three levels (basic, extended, and advanced) with competence assessment through checklists. It is directed toward both anesthesia and intensive care trainees, and provides detailed checklists for regional anesthesia, vascular access, lung ultrasound, TTE, FAST, and IVC assessment.

Other local curricula have been successfully implemented in North America. The University of California (at Irvine) has developed the Focused PeriOperative Risk Evaluation Sonography Involving Gastro-Abdominal Hemodynamic and Transthoracic ultrasound (FORESIGHT) comprehensive curriculum (28), which encompasses 24 months of training and supervised practice and competence assessment through direct observation by teachers and multiple-choice questionnaires. In contrast to the British guidelines, they don’t distinguish between basic and advanced skills but provide education in one level. The curriculum includes optic nerve sheath ultrasound, airway ultrasound, lung ultrasound, TTE, vascular access, FAST, and gastric ultrasound with specific defined objectives for each application. Another local curriculum (52) was developed by Harvard Medical School and includes a multimodal curriculum of 13 days duration and comprises on-line learning, simulators, live model scanning, and case-based discussions. The included PoCUS applications are vascular access, regional anesthesia, TTE and TEE, lung ultrasound, FAST, and abdominal ultrasound. Final assessment is based on a detailed checklist and competence is assessed through multiple-choice testing.

Table 2
I-AIM Framework

Indication	What is the diagnostic question we are trying to answer? For PoCUS, this is mostly a binary answer (yes/no)
Acquisition	What are the correct views? What structures do we need to visualize?
Interpretation	How do we interpret these findings?
Medical Decision-making	How does the information we have obtained help us guide patient management?

These articles show that there is currently no general consensus on what constitutes PoCUS education, although many authors recognize the benefit of PoCUS and support the development of international standards (44). The published PoCUS curricula and guidelines propose similar structures of basic ultrasound knowledge building, followed by supervised training and skill development for acquisition and interpretation of images. A more systematic and standardized approach to PoCUS training can be found in the I-AIM (Indication, Acquisition, Interpretation, Medical decision-making) framework (53) (Table 2). This presents an intuitive framework and logical stepwise approach to PoCUS examinations and was designed to improve the performance of the instrument and avoid potential harm. The I-AIM framework has already been developed and clinically applied to FAST (53), gastric (54) and lung ultrasound (55).

TOWARDS A STRUCTURED POCUS PATHWAY FOR BELGIAN ANESTHESIA RESIDENTS

The previously described curricula and I-AIM framework could serve as a guide for integration of PoCUS training during residency and additionally be used as a centre pass for the general anesthesia residency training program in Belgium (Figure 1).

We suggest the following approach :

Step 1 : Pre-course e-learning material, mannequin-based basic skills teaching, and simulator-based training should be mandatory before applying PoCUS in clinical practice. These methods allow time-efficient, focused, uninterrupted and safe learning, without the impact of interference on clinical practice nor subjecting patients to possible harm.

Step 2 : The introduction to clinical practice should ideally occur in a dedicated PoCUS facility guided by a certified expert. Apprentices can devote time to individualized clinical case-based learning—and acquire the minimal requirements of their PoCUS skills. These requirements should be assessed and supervised by a certified expert at the bedside of the patient.

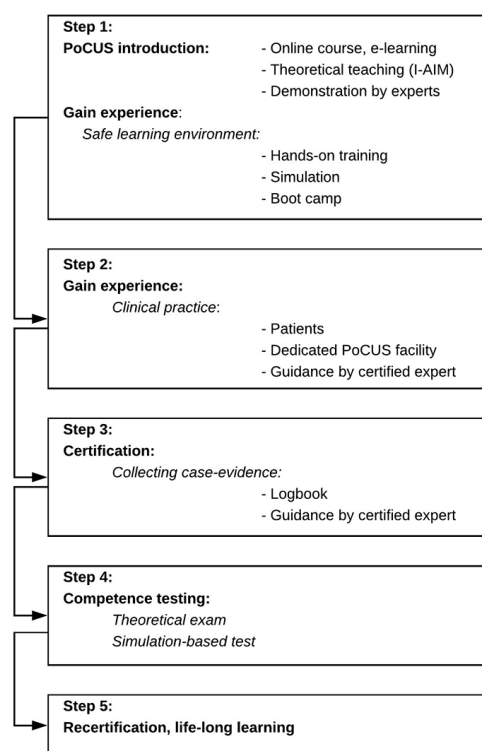


Fig. 1. — Point-of-Care pathway.

Step 3 : The next step in the official certification process is collecting case evidence. The evaluation of the number of cases, the correct image acquisition and its interpretation can be assessed post factum by a certified expert. Of course, the trainee’s exposure and training are determined by the faculty’s proficiency in PoCUS. This might be a concern as many teachers only have expert knowledge in one specified PoCUS field.

Step 4 : The final step in the certification process covers a theoretical exam together with a practical simulation-based test. The complete certification process, including a final exam and test, is the best way to ensure that those using the technology have the cognitive competency and the clinical skills to perform PoCUS.

Step 5 : Recertification is not common in Belgium but in line with individual (e.g. the TEE recertification by the European Association of Cardiovascular and Thoracic Anesthesiologists) and hospital-oriented recertification pathways (e.g.

Joint Commission International) and will probably be a future requisite.

PoCUS is causing a paradigm shift in perioperative anesthetic care. Nevertheless, it has not yet become part of the anesthesia residency. Therefore, we support its incorporation into anesthesiology curricula and training programs and the continuing professional development of PoCUS-related activities at a national level. Although it is clear from the implementation of e.g. ultrasound-guided loco-regional anesthesia that such process takes a long time, we should benefit from previous experience gained in the field of loco-regional and cardiac ultrasound to advance decisively. This requires a joint effort, supported and guided by universities and national professional societies. Implementing could additionally be government-stimulated with adapted accreditation or remuneration.

CONCLUSION

PoCUS has particular relevance to our perioperative practice. This review defines the benefits of PoCUS to anesthesia practice, identifies the different applications for PoCUS in routine anesthesia care, and suggests future perspectives to help guiding its incorporation into the Belgian anesthesia practice.

References

- Holt N.F. 2014. Trends in healthcare and the role of the anesthesiologist in the perioperative surgical home – the US perspective. *Curr. Opin. Anesthesiol.* 27: 371-376.
- Kingwill A., Barker G. and Wong A. 2017. Point-of-care ultrasound: its growing application in hospital medicine. *Br. J. Hosp. Med.* 78: 492-496.
- Millington S.J., Goffi A. and Arntfield R.T. 2018. Critical care echocardiography: a certification pathway for advanced users. *Can. J. Anesth. Can. d'anesthésie* 65: 345-349.
- Smallwood N. and Dachsel M. 2018. Point-of-care ultrasound (POCUS): unnecessary gadgetry or evidence-based medicine? *Clin. Med.* 18: 219-224.
- Kendall J.L., Hoffenberg S.R. and Smith R.S. 2007. History of emergency and critical care ultrasound: The evolution of a new imaging paradigm. *Crit. Care Med.* 35: S126-130.
- Rosenfield D., Kwan C. and Fischer J. 2015. Point-of-care ultrasound: An emerging technology in Canadian paediatrics. *Paediatr. Child Health* 20: 67-68.
- Bryson G.L. and Grocott H.P. 2018. Point-of-care ultrasound: a protean opportunity for perioperative care. *Can. J. Anesth. Can. d'anesthésie* 65: 341-344.
- Kristensen M.S. 2011. Ultrasonography in the management of the airway. *Acta Anaesthesiol. Scand.* 55: 1155-1173.
- Osman A. and Sum K.M. 2016. Role of upper airway ultrasound in airway management. *J. Intensive Care* 4: 52.
- Koundal V., Rana S., Thakur R., Chauhan V., Ekke S. and Kumar M. 2019. The usefulness of point of care ultrasound (POCUS) in preanaesthetic airway assessment. *Indian J Anaesth.* 63: 1022-1028.
- Hui C.M. and Tsui B.C. 2014. Sublingual ultrasound as an assessment method for predicting difficult intubation: a pilot study. *Anaesthesia* 69: 314-319.
- Wojtczak J.A. 2012. Submandibular Sonography. *J. Ultrasound Med.* 31: 523-528.
- Gottlieb M., Holladay D. and Peksa G.D. 2018. Ultrasonography for the Confirmation of Endotracheal Tube Intubation: A Systematic Review and Meta-Analysis. *Ann. Emerg. Med.* 72: 627-636.
- Lichtenstein D.A. and Mezière G.A. 2008. Relevance of lung ultrasound in the diagnosis of acute respiratory failure: the BLUE protocol. *Chest* 134: 117-125.
- Grimberg A., Shigueoka D.C., Atallah Á.N., Ajzen S. and Iared W. 2010. Diagnostic accuracy of sonography for pleural effusion: systematic review. *Sao Paulo Med. J.* 128: 90-95.
- Remérand F., Dellamonica J., Mao Z., Ferrari F., Bouhemad B. and Jianxin Y., et al. 2010. Multiplane ultrasound approach to quantify pleural effusion at the bedside. *Intensive Care Med.* 36: 656-664.
- Rahmani F., Parsian Z., Shahsavarinia K., Pouraghaei M., Negargar S., Mehdizadeh Esfanjani R. and Soleimanpour H. 2017. Diagnostic value of sonography for confirmation of endotracheal intubation in the emergency department. *Anesth Pain Med.* 7: e58350.
- Ramsingh D., Frank E., Haughton R., Schilling J., Gimenez K.M. and Banh E., et al. 2016. Auscultation versus Point-of-care Ultrasound to Determine Endotracheal versus Bronchial Intubation : A Diagnostic Accuracy Study. *Anesthesiology* 124: 1012-1020.
- Hu W.C., Xu L., Zhang Q., Wei L. and Zhang W. 2018. Point-of-care ultrasound versus auscultation in determining the position of double-lumen tube. *Medicine (Baltimore).* 97: e9311.
- Alrajab S., Youssef A.M., Akkus N.I. and Caldito G. 2013. Pleural ultrasonography versus chest radiography for the diagnosis of pneumothorax: review of the literature and meta-analysis. *Crit. Care* 17: R208-R208.
- Al Deeb M., Barbic S., Featherstone R., Dankoff J. and Barbic D. 2014. Point-of-care Ultrasonography for the Diagnosis of Acute Cardiogenic Pulmonary Edema in Patients Presenting With Acute Dyspnea: A Systematic Review and Meta-analysis. *Acad. Emerg. Med.* 21: 843-852.
- Bouchez S. and Wouters P. 2020. Chapter 17: The Role of Ultrasound in Thoracic Surgery. In: *Anesthesia in Thoracic Surgery – Changes of Paradigms*. Springer International Publishing.
- Mercaldi C.J. and Lanes S.F. 2013. Ultrasound Guidance Decreases Complications and Improves the Cost of Care Among Patients Undergoing Thoracentesis and Paracentesis. *Chest* 143: 532-538.
- Mosier J., Martin J., Andrus P., Clinton M., Demla V. and Am Dinh V., et al. 2018. Advanced Hemodynamic and Cardiopulmonary Ultrasound for Critically Ill Patients in the Emergency Department. *Emerg. Med.* 50: 17-34.
- Cannesson M., Sliker J., Desebbe O., Farhat F., Bastien O. and Lehot J.J. 2006. Prediction of fluid responsiveness using respiratory variations in left ventricular stroke area by transoesophageal echocardiographic automated border detection in mechanically ventilated patients. *Crit. Care* 10: R171.
- Charron C., Caille V., Jardin F. and Vieillard-Baron A. 2006. Echocardiographic measurement of fluid responsiveness. *Curr. Opin. Crit. Care* 12: 249-254.
- Bouchez S. and Wouters P. 2019. Echocardiography in the Intensive Care Unit. *Curr. Anesthesiol. Rep.* 9: 360-367.

28. Ramsingh D., Rinehart J., Kain Z., Strom S., Canales C. and Alexander B., et al. 2015. Impact Assessment of Perioperative Point-of-Care Ultrasound Training on Anesthesiology Residents. *Anesthesiol. J. Am. Soc. Anesthesiol.* 123: 670-682.
29. Backer D.D. and Fagnoul D. 2014. Intensive care ultrasound: VI. Fluid responsiveness and shock assessment. *Ann Am Thorac Soc* 11: 129-136.
30. Kobal S.L., Trento L., Baharami S., Tolstrup K., Naqvi T.Z. and Cercek B., et al. 2005. Comparison of Effectiveness of Hand-Carried Ultrasound to Bedside Cardiovascular Physical Examination. *Am. J. Cardiol.* 96: 1002-1006.
31. McCormick T.J., Miller E.C., Chen R. and Naik V.N. 2018. Acquiring and maintaining point-of-care ultrasound (POCUS) competence for anesthesiologists. *Can J Anesth* 65: 427-436.
32. Tsang T.S., Enriquez-Sarano M., Freeman W.K., Barnes M.E., Sinak L.J. and Gersh B.J., et al. 2002. Consecutive 1127 Therapeutic Echocardiographically Guided Pericardiocenteses: Clinical Profile, Practice Patterns, and Outcomes Spanning 21 Years. *Mayo Clin. Proc.* 77: 429-436.
33. Egan G., Healy D., O'Neill H., Clarke-Moloney M., Grace P.A. and Walsh S.R. 2013. Ultrasound guidance for difficult peripheral venous access: systematic review and meta-analysis. *Emerg. Med. J.* 30: 521-526.
34. Lamperti M., Bodenham A.R., Pittiruti M., Blaivas M., Augoustides J.G. and Elbarbary M., et al. 2012. International evidence-based recommendations on ultrasound-guided vascular access. *Intensive Care Med.* 38: 1105-1117.
35. Shiloh A.L., Savel R.H., Paulin L.M. and Eisen L.A. 2011. Ultrasound-Guided Catheterization of the Radial Artery: A Systematic Review and Meta-analysis of Randomized Controlled Trials. *Chest* 139: 524-529.
36. Tarique U., Tang B., Singh M., Kulasegaram K.M. and Ailon J. 2018. Ultrasound curricula in undergraduate medical education: A scoping review. *J. Ultrasound Med.* 37: 69-82.
37. Abu-Zidan F.M. and Cevik A.A. 2018. Diagnostic point-of-care ultrasound (POCUS) for gastrointestinal pathology: state of the art from basics to advanced. *World J. Emerg. Surg.* 13: 47.
38. Williams S.R., Perera P. and Gharahbaghian L. 2014. The FAST and E-FAST in 2013: Trauma Ultrasonography: Overview, Practical Techniques, Controversies, and New Frontiers. *Crit. Care Clin.* 30, 119-150.
39. Concannon E., McHugh S., Healy D.A., Kavanagh E., Burke P., Clarke Moloney M. and Walsh S.R. 2014. Diagnostic accuracy of non-radiologist performed ultrasound for abdominal aortic aneurysm: systematic review and meta-analysis. *Int. J. Clin. Pract.* 68: 1122-1129.
40. Van De Putte P. and Perlas A. 2014. Ultrasound assessment of gastric content and volume. *Br. J. Anaesth.* 113: 12-22.
41. Gagey A.C., de Queiroz Siqueira M., Monard C., Combet S., Cogniat B. and Desgranges F.P., et al. 2018. The effect of pre-operative gastric ultrasound examination on the choice of general anaesthetic induction technique for non-elective paediatric surgery. A prospective cohort study. *Anaesthesia.* 73: 304-312.
42. Shah S., Adedipe A., Ruffatto B., Backlund B.H., Sajed D., Rood K. and Fernandez R. 2014. BE-SAFE: Bedside sonography for assessment of the fetus in emergencies: educational intervention for late-pregnancy obstetric ultrasound. *West. J. Emerg. Med.* 15: 636-640.
43. Cho J., Jensen T.P., Reiersen K., Mathews B.K., Bhagra A. and Franco-Sadud R., et al. 2019. Recommendations on the Use of Ultrasound Guidance for Adult Abdominal Paracentesis: A Position Statement of the Society of Hospital Medicine. *J. Hosp. Med.* 14: E7-E15.
44. Meineri M., Bryson G.L., Arellano R. and Skubas N. 2018. Core point-of-care ultrasound curriculum : What does every anesthesiologist need to know? *Can. J. Anesth.* 65: 417-426.
45. Mahmood F., Matyal R., Skubas N., Montealegre-Gallegos M., Swaminathan M. and Denault A., et al. 2016. Perioperative Ultrasound Training in Anesthesiology: A Call to Action. *Anesth. Analg.* 122: 1794-1804.
46. Johnson D.W. and Oren-Grinberg A. 2011. Perioperative Point-of-Care Ultrasonography: The Past and the Future Are in Anesthesiologists' Hands. *Anesthesiol. J. Am. Soc. Anesthesiol.* 115: 460-462.
47. Sanders J.A., Navas-Blanco J.R., Yeldo N.S., Han X., Guruswamy J. and Williams D.V. 2019. Incorporating Perioperative Point-of-Care Ultrasound as Part of the Anesthesia Residency Curriculum. *J. Cardiothorac. Vasc. Anesth.* 33: 2414-2418.
48. McCormick T.J., Miller E.C., Chen R. and Naik V.N. 2018. Acquiring and maintaining point-of-care ultrasound (POCUS) competence for anesthesiologists. *Can. J. Anesth.* 65: 427-436.
49. Ramsingh D., Fox J.C. and Wilson W.C. 2015. Perioperative Point-of-Care Ultrasonography: An Emerging Technology to Be Embraced by Anesthesiologists. *Anesth. Analg.* 120: 990-992.
50. De Marchi L. and Meineri M. 2017. POCUS in perioperative medicine: a North American perspective. *Crit. Ultrasound J.* 9: 19.
51. Ultrasound in Anaesthesia and Intensive Care : A Guide to Training. https://anaesthetists.org/Portals/0/PDFs/Guidelines/PDFs/Guideline_ultrasound_anaesthesia_intensive_care_guide_training_2011_final.pdf?ver=2018-07-11-163758-490&ver=2018-07-11-163758-490.
52. Mitchell J.D., Montealegre-Gallegos M., Mahmood F., Owais K., Wong V. and Ferla B., et al. 2015. Multimodal Perioperative Ultrasound Course for Interns Allows for Enhanced Acquisition and Retention of Skills and Knowledge. *A&A Pract.* 5: 119-123.
53. Bahner D.P., Hughes D. and Royall N.A. 2012. I-AIM. *J. Ultrasound Med.* 31: 295-300.
54. Perlas A., Van de Putte P., Van Houwe P. and Chan V.W.S. 2016. I-AIM framework for point-of-care gastric ultrasound. *Br J Anaesth.* 116: 7-11.
55. Kruisselbrink R., Chan V., Cibinel G.A., Abrahamson S. and Goffi A. 2017. I-AIM (Indication, Acquisition, Interpretation, Medical Decision-making) Framework for Point of Care Lung Ultrasound. *Anesthesiol. J. Am. Soc. Anesthesiol.* 127: 568-582.